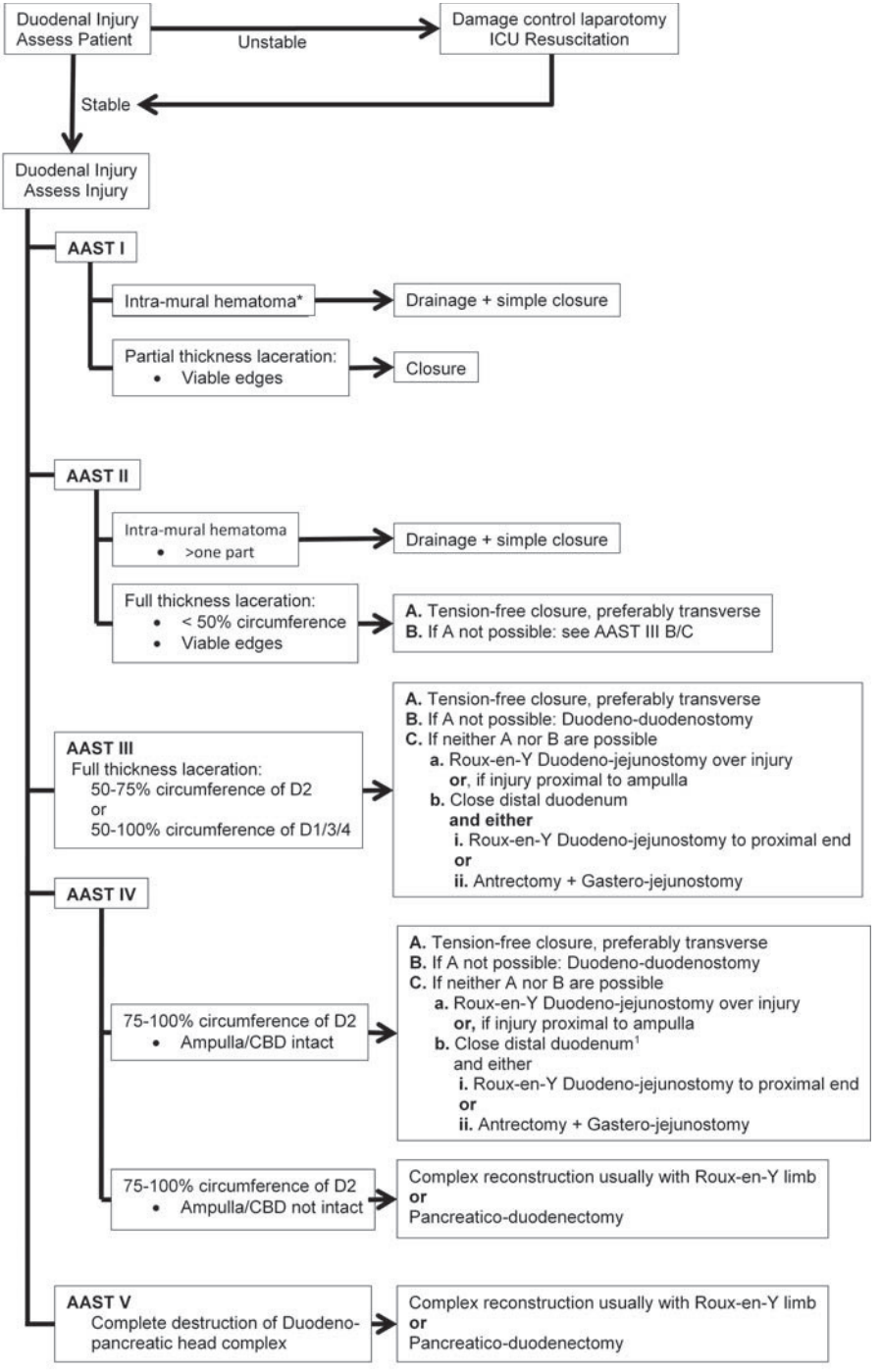
Duodenal Injury
Assess Patient
Unstable
Damage control laparotomy
ICU Resuscitation
Stable
Duodenal Injury
Assess Injury
AAST I
Intra-mural hematoma*
Drainage + simple closure
Partial thickness laceration:
• Viable edges
Closure
AAST II
Intra-mural hematoma
• >one part
Drainage + simple closure
Full thickness laceration:
• < 50% circumference
• Viable edges
A. Tension-free closure, preferably transverse
B. If A not possible: see AAST III B/C
AAST III
Full thickness laceration:
50-75% circumference of D2
or
50-100% circumference of D1/3/4
A. Tension-free closure, preferably transverse
B. If A not possible: Duodeno-duodenostomy
C. If neither A nor B are possible
a. Roux-en-Y Duodeno-jejunostomy over injury
or, if injury proximal to ampulla
b. Close distal duodenum
and either
i. Roux-en-Y Duodeno-jejunostomy to proximal end
or
ii. Antrectomy + Gastero-jejunostomy
AAST IV
75-100% circumference of D2
• Ampulla/CBD intact
A. Tension-free closure, preferably transverse
B. If A not possible: Duodeno-duodenostomy
C. If neither A nor B are possible
a. Roux-en-Y Duodeno-jejunostomy over injury
or, if injury proximal to ampulla
b. Close distal duodenum[1]
and either
i. Roux-en-Y Duodeno-jejunostomy to proximal end
or
ii. Antrectomy + Gastero-jejunostomy
75-100% circumference of D2
• Ampulla/CBD not intact
Complex reconstruction usually with Roux-en-Y limb
or
Pancreatico-duodenectomy
AAST V
Complete destruction of Duodeno-pancreatic head complex
Complex reconstruction usually with Roux-en-Y limb
or
Pancreatico-duodenectomy